

T3[®] PRO


Implant Clinical Cases



 **ZimVie**

Table of Contents

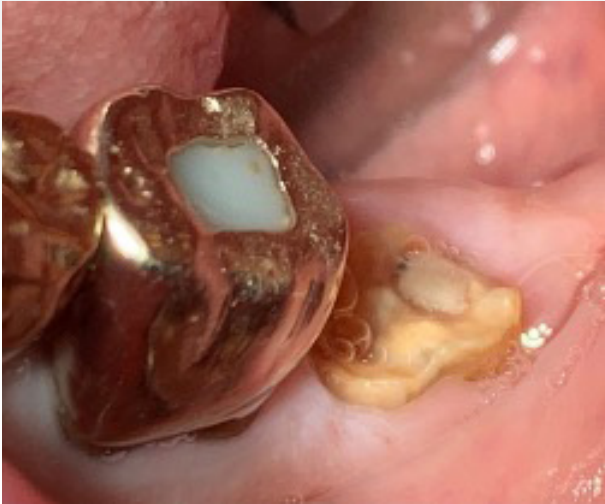T3 PRO Implant immediate placement in second molar	3 - 5
T3 PRO Implant placed in the first molar and then restored after three months of healing	6 - 7
T3 PRO Implant immediate placement in lateral incisor.....	8 - 9
Five-year post-operative evaluation of T3 Implant in lower right second molar and initial placement of T3 PRO Implant in lower left second molar.....	10 - 11
Ordering Information.....	12



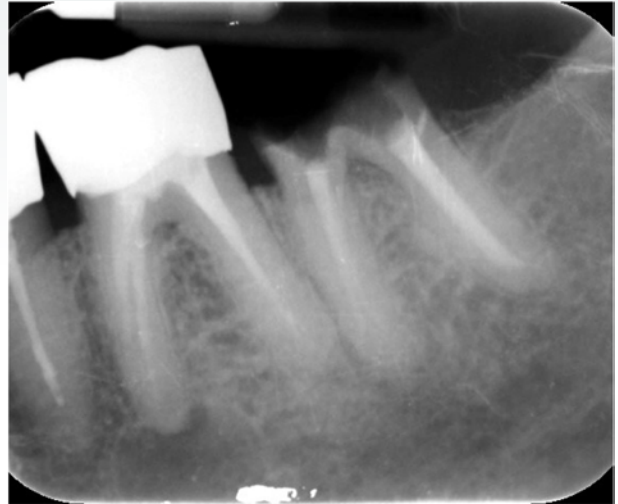Case 1

T3 PRO Implant immediate placement in second molar

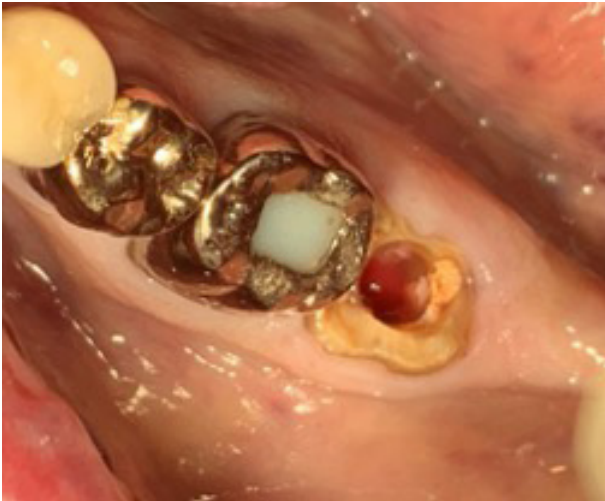Patient profile: 80 yrs; Diabetic, Non-Smoker; Medication: Omeprazole and Metformin



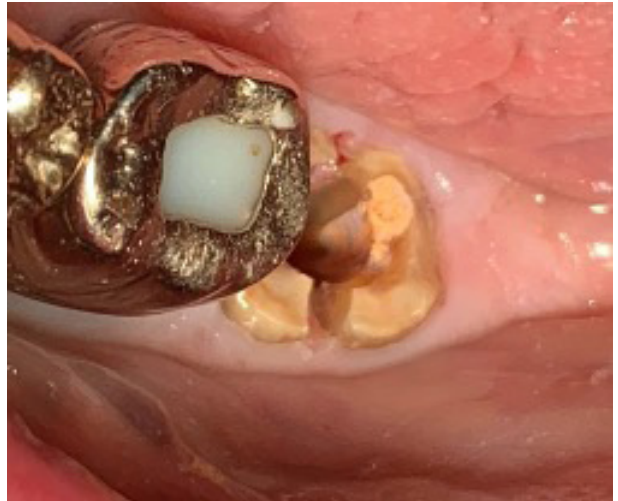- Pre-op photo (second molar)



- Pre-op radiograph



- Site prep through the molar with drill up to 5 mm diameter

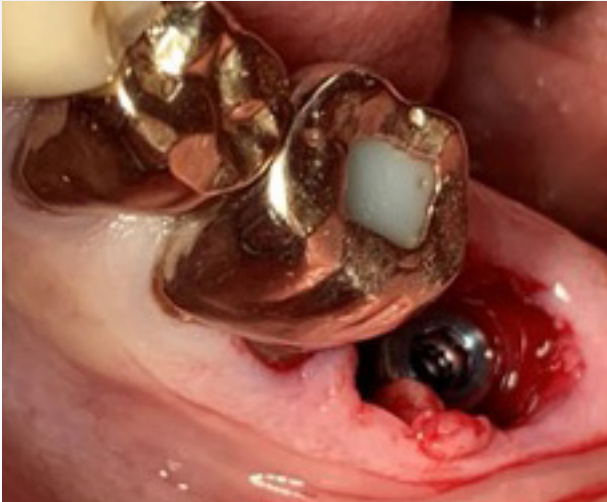

- Separation of the mesial and lingual root, followed by molar extraction
- The socket walls were excavated

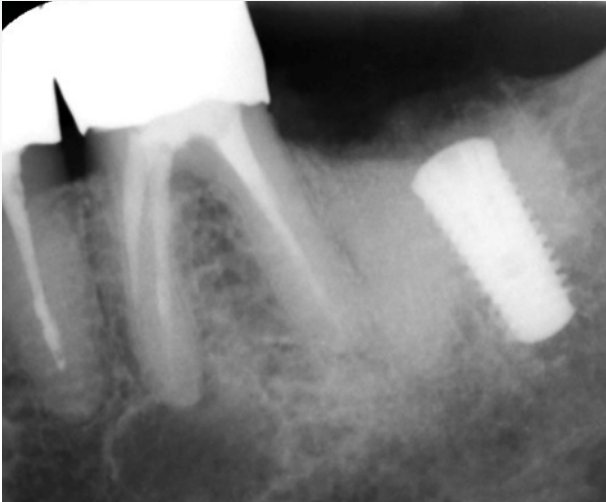Clinical photographs courtesy of Dr. Maarten J. Boogaard. Individual results may vary.

Case 1 continued

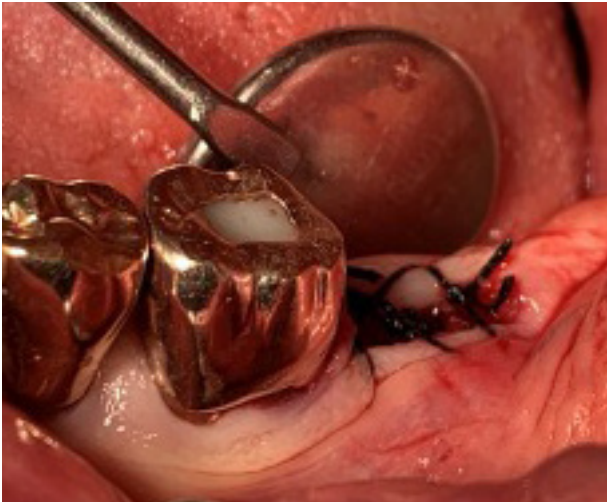
T3 PRO Implant immediate placement in second molar



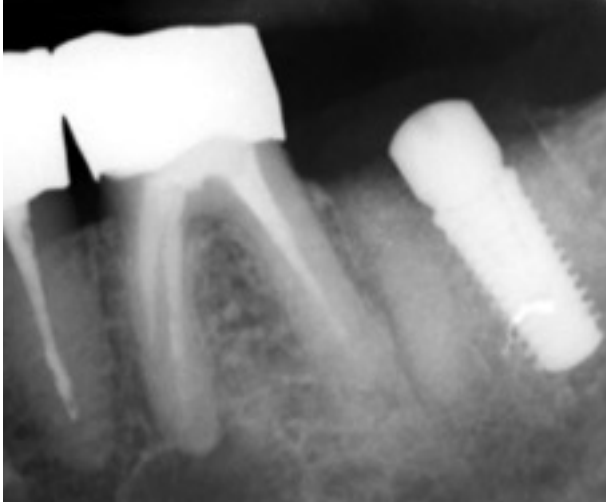
- After site preparation, a platform switched T3 PRO Implant (T3PT5411) was placed in extraction socket
- 45 Ncm final seating torque was achieved



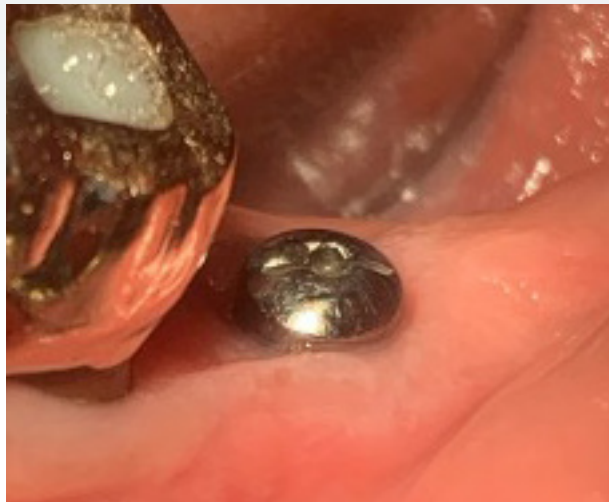- Bone graft putty was applied to fill the gap between implant and the socket walls
- An OsseoGuard® flex membrane was placed over the implant



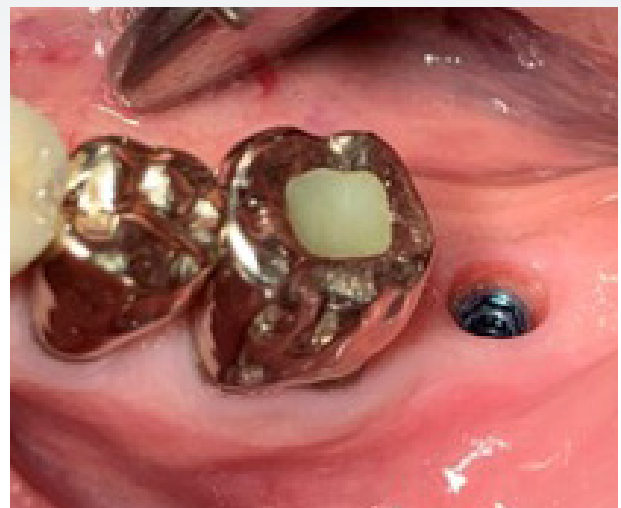
- Healing abutment is attached right after implant placement
- Site allowed to heal with healing abutment on implant



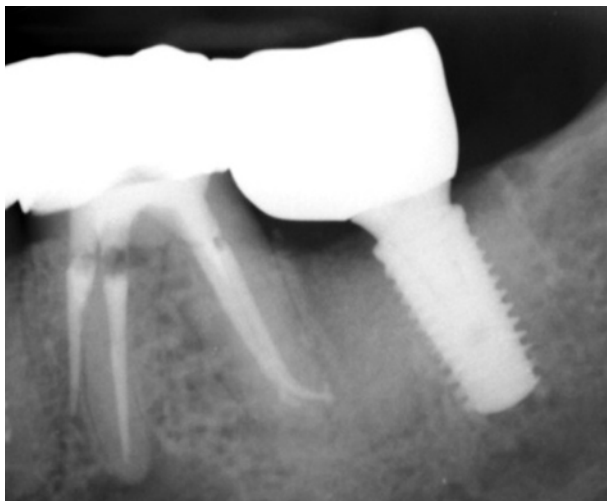
- Post-operative radiograph with healing abutment was placed



- Image shows healed site with the healing abutment three months after implant placement



- Clinician reported good stability and natural emergence profile three months after implant placement
- Case was restored using patient-specific screw-retained abutment three months after implant placement



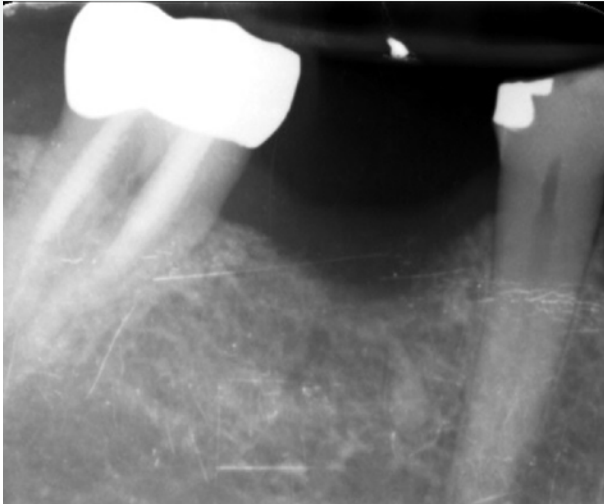
- Radiograph after crown placement
- Crown attached four months after implant placement
- Image shows a radiograph taken four months and three weeks after implant placement

Clinical photographs courtesy of Dr. Maarten J. Boogaard. Individual results may vary.

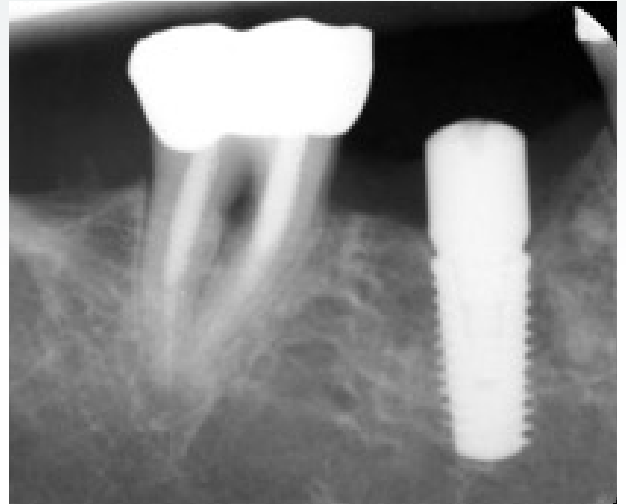
Case 2

T3 PRO Implant placed in the first molar and then restored after three months of healing

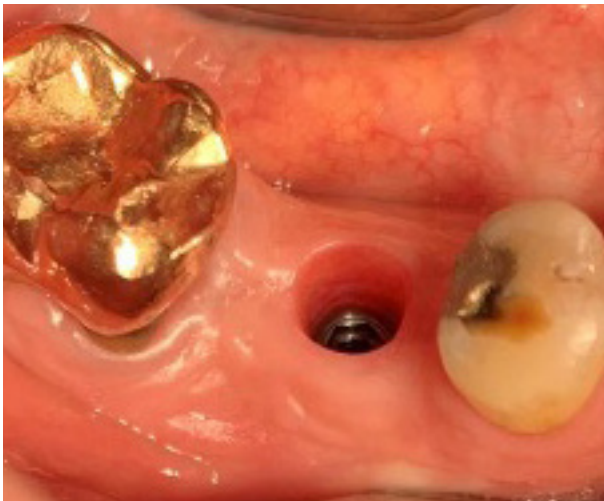Patient profile: 54 yrs; No medication, Non-Smoker, Healthy



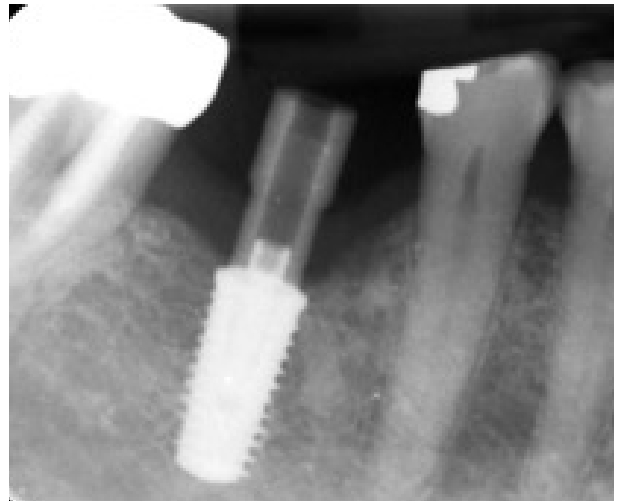- Pre-op radiograph showing missing first molar



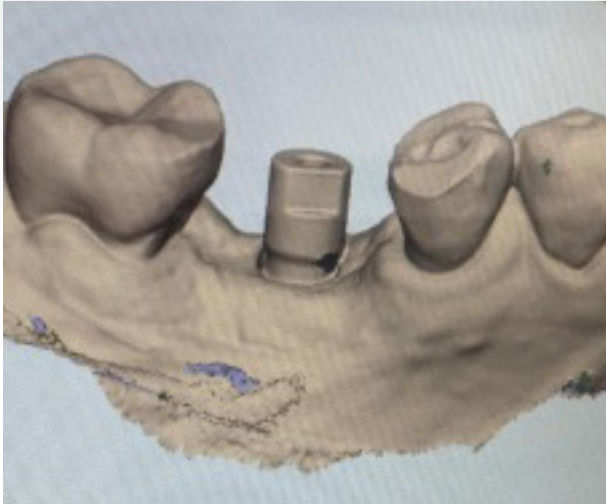

- T3 PRO Implant placed with 45 Ncm torque
- Image shows post-placement radiograph taken with healing abutment attached to the implant



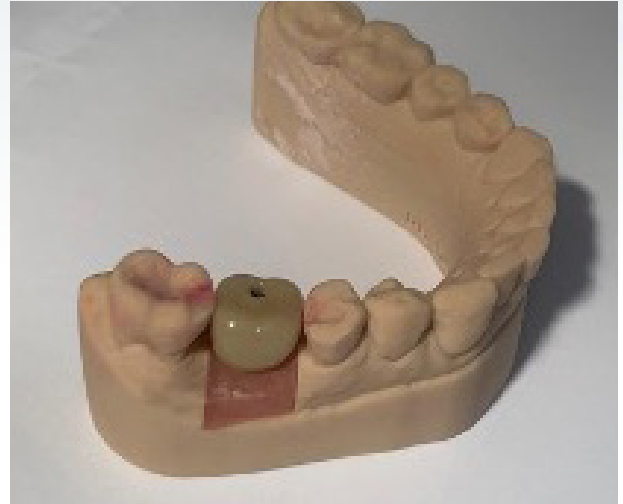- Clinician reported excellent emergence profile three months after healing



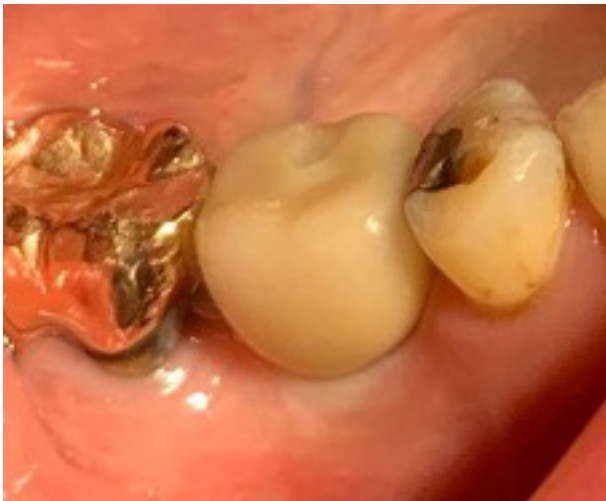- Radiograph (three months post-op) with scannable abutment attached



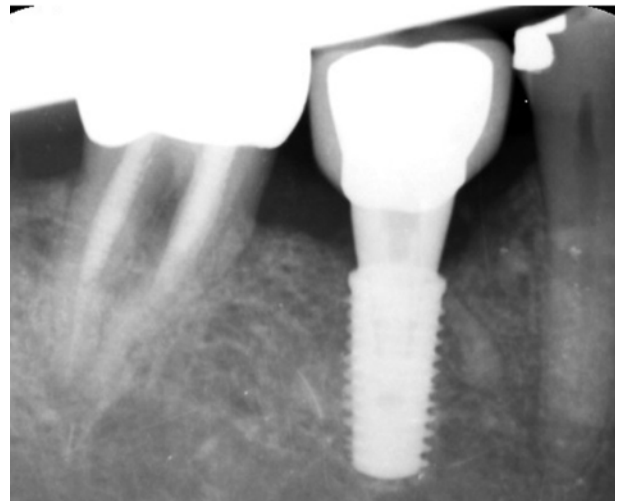- 3D rendering with scannable abutment



- 3D printed model created from scan



- Implant restored with patient-specific abutment and crown attached at 30 Ncm torque



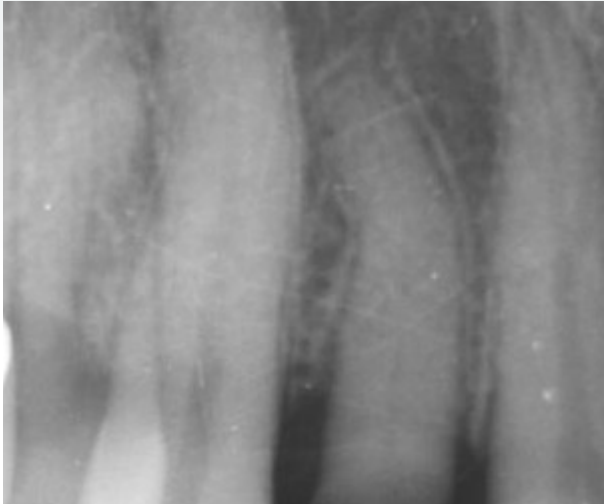
- Radiograph with crown attached taken three months and three weeks after implant placement

Clinical photographs courtesy of Dr. Maarten J. Boogaard. Individual results may vary.

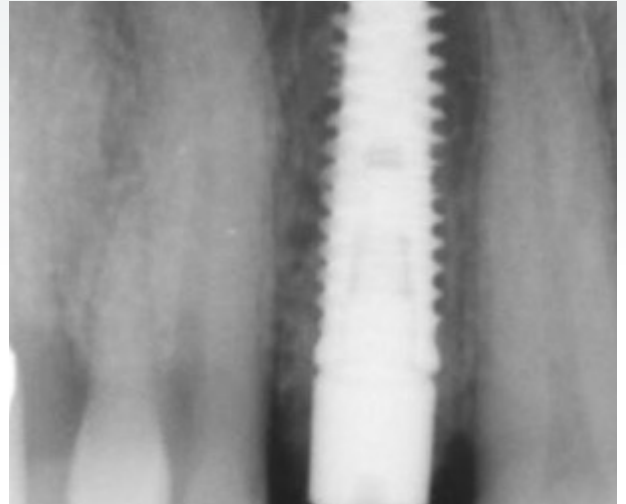
Case 3

T3 PRO Implant immediate placement in lateral incisor

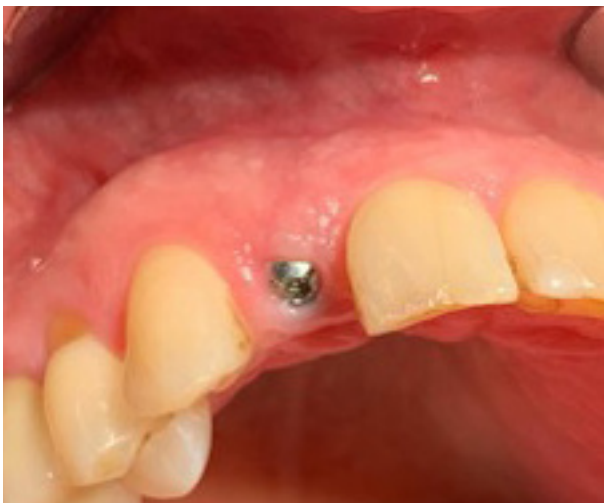Patient profile: 50 yrs; No medication, Non-Smoker, Healthy



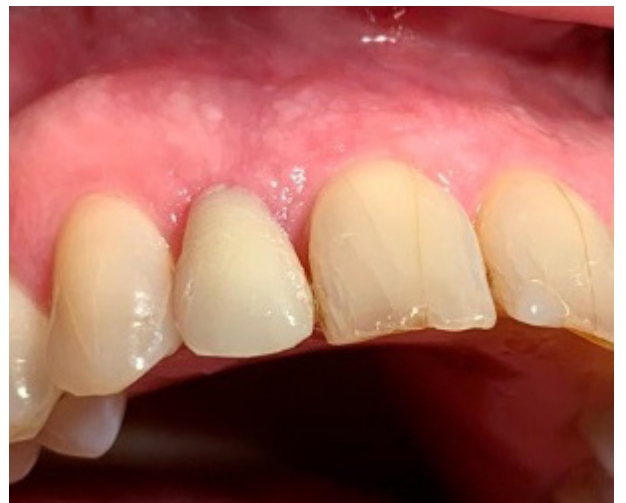- Pre-op radiograph (lateral incisor)



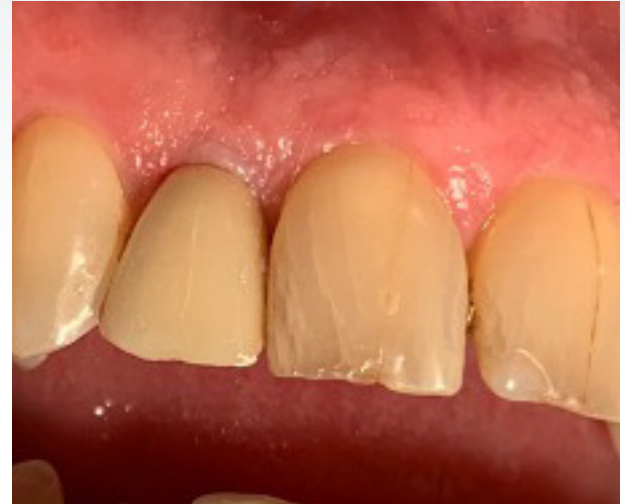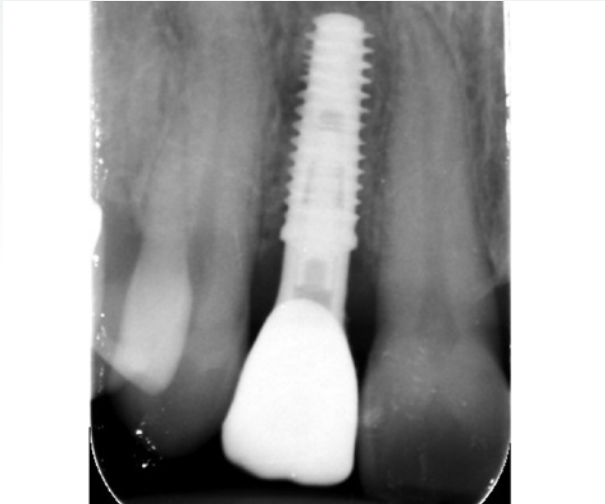- T3 PRO Implant 4 mmD X 11 mmL placed and healing abutment attached
- Gap around implant filled with bone graft putty



- Image after two weeks of healing period shows excellent soft tissue coverage



- Provisional placed at the two-week follow-up after implant placement



- Case restored with patient-specific abutment four months after implant placement
- Radiograph taken with crown attached

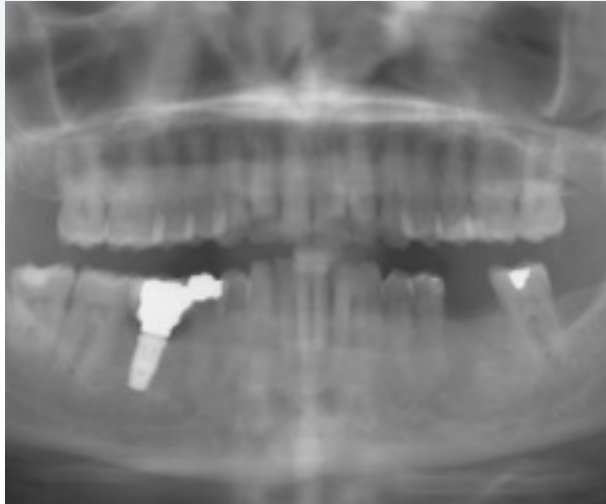
- Photo after crown placement showing ideal soft tissue contours



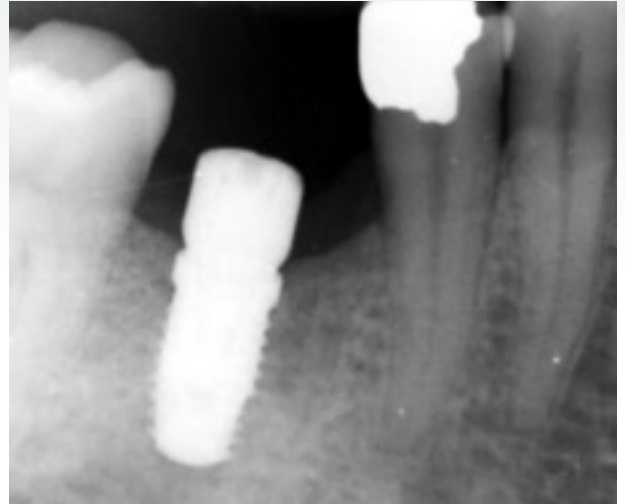
Case 4

Five-year post-operative evaluation of T3 Implant in lower right second molar and initial placement of T3 PRO Implant in lower left second molar

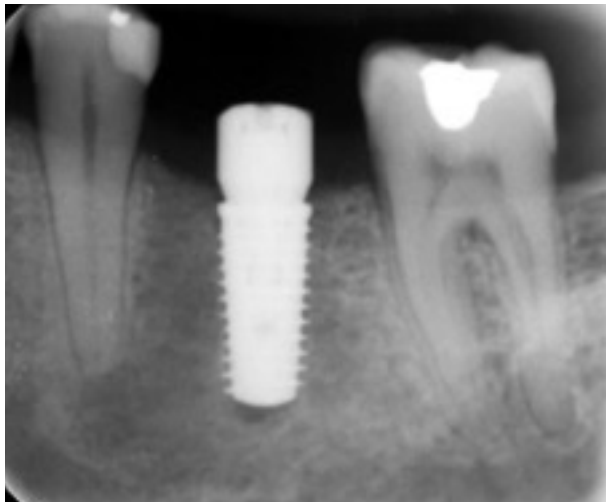
Patient profile: 63 yrs; No medication, Non-Smoker, Healthy



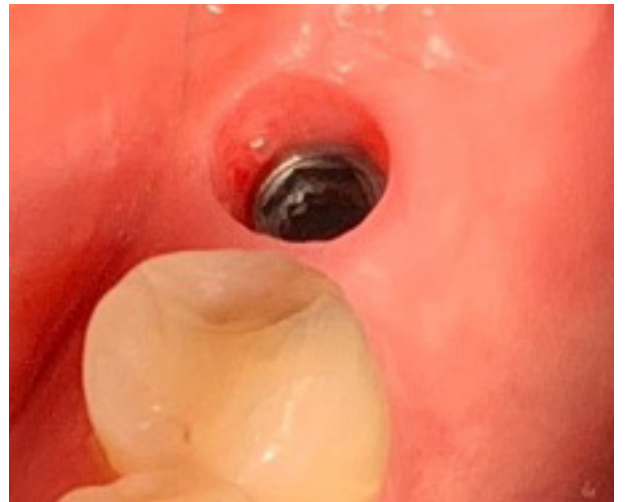- Five year post-operative radiograph shows a 5 mmD x 11 mmL T3 in lower right first molar
The final seating torque was 35 Ncm
- The same patient will receive a 5 mmD x 11 mmL T3 PRO Implant in lower left first molar



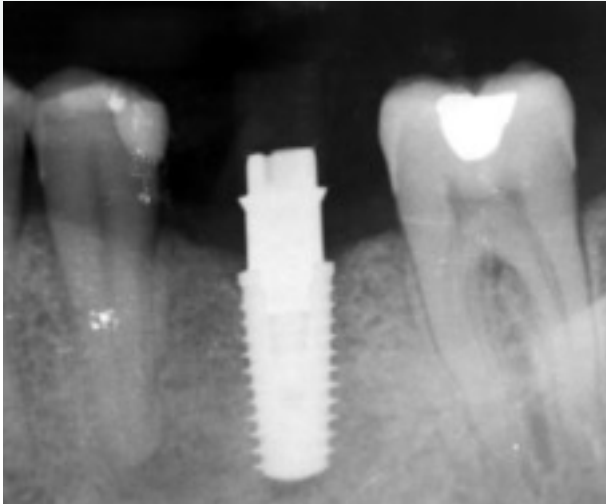
- Closer look at the 5 mmD x11 mmL T3 in the lower right first molar
- Clinician reported excellent crestal bone level at 5 years post-op



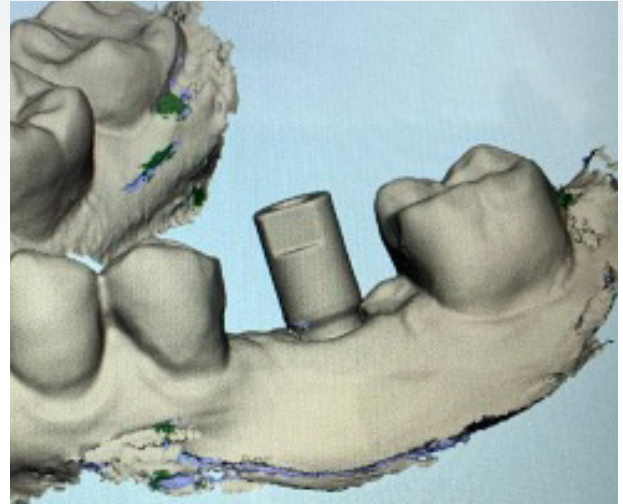
- Radiograph after placement of a T3 PRO Implant 5 mmD x 11 mmL and a healing abutment
- Final Insertion torque recorded was 70 Ncm



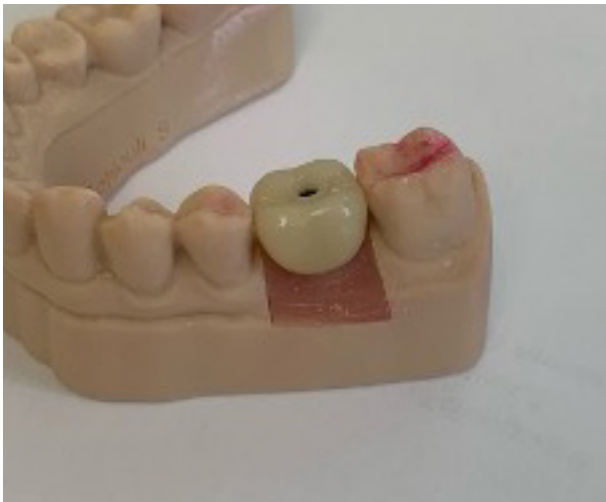- 3.5 months post-operative photo
- Clinician reported excellent emergence profile



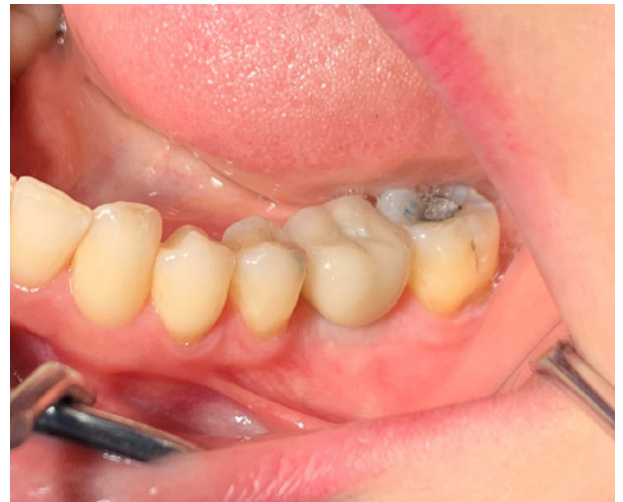- Radiograph with scannable abutment at 6.5 months post-op



- 3D rendering with scannable abutment



- 3D printed model created from scan



- Case restored with patient-specific abutment
- Photo with crown attached taken at 4 months post-op shows ideal soft tissue contours

Clinical photographs courtesy of Dr. Maarten J. Boogaard. Individual results may vary.

Ordering Information

T3 PRO Implant Platform Switched



	Length				
	8.5 mm	10 mm	11.5 mm	13 mm	15 mm
4D/3P mm	T3PT4385	T3PT4310	T3PT4311	T3PT4313	T3PT4315
5D/4P mm	T3PT5485	T3PT5410	T3PT5411	T3PT5413	T3PT5415
6D/5P mm	T3PT6585	T3PT6510	T3PT6511	T3PT6513	T3PT6515

D = Implant body diameter
P = Diameter of prosthetic platform

T3 PRO Implant Non-Platform Switched



	Length				
	8.5 mm	10 mm	11.5 mm	13 mm	15 mm
3.25 mm D	T3ST3285	T3ST3210	T3ST3211	T3ST3213	T3ST3215
4 mm D	T3ST485	T3ST410	T3ST411	T3ST413	T3ST415
5 mm D	T3ST585	T3ST510	T3ST511	T3ST513	T3ST515
6 mm D	T3ST685	T3ST610	T3ST611	T3ST613	T3ST615

For more information, visit ZimVie.com

ZimVie
4555 Riverside Drive
Palm Beach Gardens, FL 33410
Phone: +1-561-776-6700
Fax: +1-561-776-1272

 **ZimVie**
Restoring Daily Life.™

Unless otherwise indicated, as referenced herein, all trademarks and intellectual property rights are the property of ZimVie Inc. or an affiliate; and all products are manufactured by one or more of the dental subsidiaries of ZimVie Inc. (Biomet 3i, LLC, Zimmer Dental, Inc., etc.) and marketed and distributed by ZimVie Dental and its authorized marketing partners. All third-party product names and trademarks are the property of their respective owners. ZimVie is an authorized distributor of iTero Products, which are manufactured by Align Technology, Inc. For additional product information, please refer to the individual product labeling or instructions for use. Product clearance and availability may be limited to certain countries/regions. This material is intended for clinicians only and does not comprise medical advice or recommendations. Distribution to any other recipient is prohibited. This material may not be copied or reprinted without the express written consent of ZimVie. ZV2422 REV A 10/24 ©2024 ZimVie. All rights reserved.